

Technical Note

The Zipknot Technique: A Modified Tension Band Repair Technique for Isolated Supraspinatus Tears

Vincent Martinel, M.D., and Bruno Zipoli, M.D.

Abstract: Tension band repair frequently is used for small rotator cuff tears. This Technical Note describes a variation using a single knotless suture anchor but with a specific lark's head knot technique to pass the sutures through the tendon that improves bone–tendon contact and tendon healing while preventing a dog-ear deformity.

Numerous techniques have been described to repair large rotator cuff tears, but there are very few articles describing the repair of small- or medium-sized supraspinatus tears.¹ During a period when it is important to reduce the costs of surgical procedures and their carbon footprint, simple, reliable repair techniques should be taken into consideration.² Although tension band repair has long been indicated in these cases,³ there is less bone–tendon contact with this procedure compared with double-row techniques.⁴ We present a single knotless suture anchor and tension band technique that combines the use of suture tape and cord suture, with improved bone–tendon contact as a result of a crisscross effect, thanks to use of lark's head knot.

Surgical Technique (With Video Illustration)

Preoperative Evaluation

The Zipknot technique is indicated in patients with symptomatic superior rotator cuff tears and with no risk

factors for poor healing, in particular, nonsmokers without hypercholesterolemia. Magnetic resonance imaging or a computed tomography arthrogram must be performed to evaluate the size of the tear on the anteroposterior plane, which should ideally be between 0.5 and 2 cm for this technique. More anchors are recommended for larger tears. Tendon retraction is assessed on imaging on the frontal plane and the muscular fatty infiltration index should be measured and should ideally be less than 2.

Surgery

Demonstration of arthroscopic rotator cuff repair of a left shoulder using the Zipknot technique is presented in [Video 1](#). The advantages and disadvantages of the technique are listed in [Table 1](#) and the pearls and pitfalls in [Table 2](#). Surgery is performed with the patient under interscalene block and general anesthesia. The patient is placed in the lateral decubitus position, but the arthroscope is turned 90° to obtain a vertical view like that in the beach-chair position. The arm is stabilized with a conventional traction system. A transparent operating field is created after the skin has been prepared. Three portals are used: a posterior portal and an anterior portal, mainly for instrumentation and a lateral portal, mainly for the arthroscope.

The first step is to prepare and expose the superficial layer of the rotator cuff with the arthroscope in the posterior portal and the instruments in the lateral portal. A cannula may be placed in the lateral portal (PassPort Button; Arthrex, Naples, FL) but is not absolutely necessary. The arthroscope is then inserted through this cannula in the lateral portal to control the anterior and posterior portals.

A crochet-hook suture passer (clever hook; SBM, Lourdes, France) is used to pass a cord suture (Power-tex suture; SBM), which is made of polyethylene with a

From the Groupe Orthopédie Ormeau Pyrénées, ELSAN - Polyclinique de l'Ormeau, Tarbes, France (V.M.); and Service orthopédie et traumatologie, centre hospitalier de Dax, Dax, France (B.Z.).

The authors report the following potential conflicts of interest or sources of funding: V.M. and B.Z. receive royalties from, have made paid presentations for, and are consultants for SBM. Full ICMJE author disclosure forms are available for this article online, as [supplementary material](#).

Received July 5, 2023; accepted August 27, 2023.

Address correspondence to Vincent Martinel, M.D., Groupe Orthopédie Ormeau Pyrénées, ELSAN - Polyclinique de l'Ormeau, 28 bvd du 8 Mai 1945, 65000 Tarbes, France. E-mail: vmartinel@me.com

© 2023 THE AUTHORS. Published by Elsevier Inc. on behalf of the Arthroscopy Association of North America. This is an open access article under the CC BY-NC-ND license (<http://creativecommons.org/licenses/by-nc-nd/4.0/>).

2212-6287/23947

<https://doi.org/10.1016/j.eats.2023.08.025>

Table 1. Advantages and Disadvantages of the Zipknot Technique

Advantages	Disadvantages
One single anchor	Learning curve
One reusable screwdriver	Need to correctly center the loop
Possibility of using an automatic clamp	
Optimal contact with the cuff footprint	
Prevents dog-ear deformity	
Knotless system	
Can be used on asymmetric tears	

flat central portion that resembles a tape) and suture tape (BroadBand Suture Tape; Zimmer, The Hague, Netherlands) through the posterior rotator cuff, medial from the tear in a single pass through the posterior portal (Fig 1). The suture passer is removed, leaving the tape and suture in place to form a loop.

A crochet-hook suture passer is then inserted into the anterior portal through the rotator cuff to recover the 2 loops and pull the tape and suture out and forward (Fig 2). Care must be taken that the 2 strands are the same length.

The middle of the tear must then be identified to place the suture passer in the medial position through the posterior portal, passing through the tendon to only recover the looped ends of the sutures on the superficial part of the supraspinatus (Fig 3). The length and width of this loop should be adjusted until the central part of the tendon is in a good position for optimal bone–tendon contact (Fig 4). Ideally, the loop should brush against the lateral edge of the tear.

A suture retriever is inserted through the posterior portal under and into the loop to grasp the anterior end of the cord suture. It is important for the suture to go through the loop by passing from above to below. This maneuver is repeated through the anterior portal to pass the posterior part of the looped suture into the loop from above to below. This creates a double loop called a

Table 2. Pearls and Pitfalls of the Zipknot Technique

Pearls	Pitfalls
- Pass 2 sutures at a time through the rotator cuff.	- Difficulty tightening the tape if the end of the anchor is too deep
- Make sure that the anterior and posterior strands are the same length	- Do not make a central loop that is too small at the beginning of the procedure
- Test bone quality with a 4.5-mm pinch tap to position an anchor that is frequently larger in diameter (5.5 mm or 6.5 mm).	

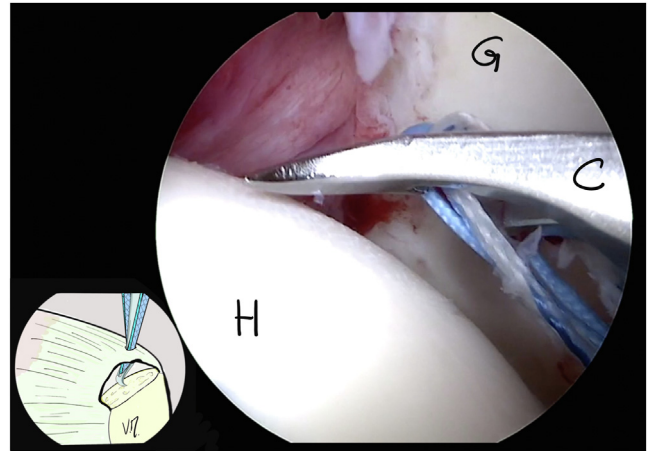


Fig 1. View through the lateral portal of a left shoulder with the arthroscope passed through the supraspinatus tear. Patient is in the lateral decubitus position. A crochet-hook suture passer (C) is inserted through the posterior part of the supraspinatus tendon to pass the tape and looped suture into the glenohumeral space. (G, glenoid; H, humeral head.)

lark's head knot (Fig 5). All of the ends of tape and looped sutures are passed through the anterior portal.

The arthroscope is then inserted through the posterior portal, and the lateral surface of the greater tubercle is debrided. A 4.5-mm punch-tap is inserted into the lateral portal, and punched into the debrided area to evaluate bone quality. All of the sutures are recovered through the lateral portal (Fig 6).

A tri-calcium phosphate biocomposite, osteoconductive absorbable suture anchor Fixit KL 5.5 mm (SBM) is used and the 2 ends of the tape and the looped

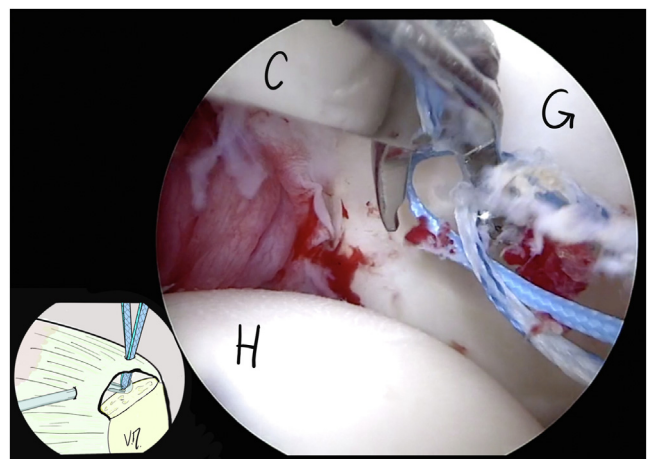


Fig 2. View through the lateral portal of the left shoulder with the arthroscope inserted through the supraspinatus tear. Patient is in the lateral decubitus position. A crochet hook suture passer (C) is passed through the anterior part of the supraspinatus tendon to recover previously passed tape and the looped suture. (G, glenoid; H, humeral head.)

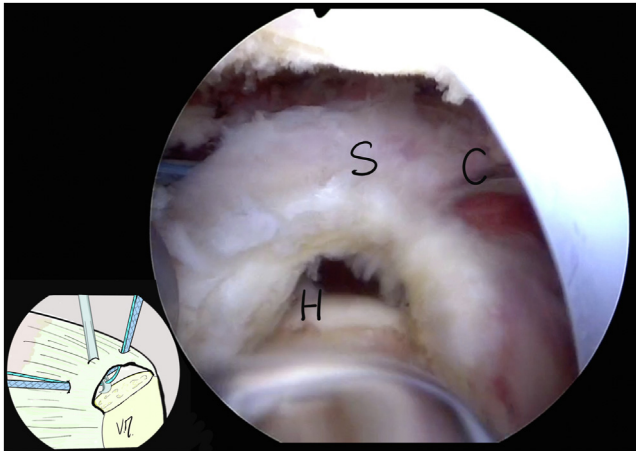


Fig 3. View through the lateral portal of the left shoulder with the arthroscope removed. Patient is in the lateral decubitus position. A crochet hook suture passer (C) is inserted through the posterior portal. The suture passer's tip pierces the supraspinatus (S) tendon in the middle, ideally half way between the anterior and posterior entry points of the sutures and is going to then bring the looped suture through the superficial part of the tendon by making a loop. (H, humeral head.)

suture are passed with a specific guide wire through a reusable screwdriver.

The anchor is positioned at the entrance to the bone tunnel, and the 4 ends of the suture are tightened in succession by hand to adjust the tension and reduce the tear. Alternating the tension of the strands makes it possible to obtain precise and appropriate repair even with asymmetric tears.

Ideally, the central loop should be tightened in a fairly lateral position and parallel to the tendon tear (Fig 7).

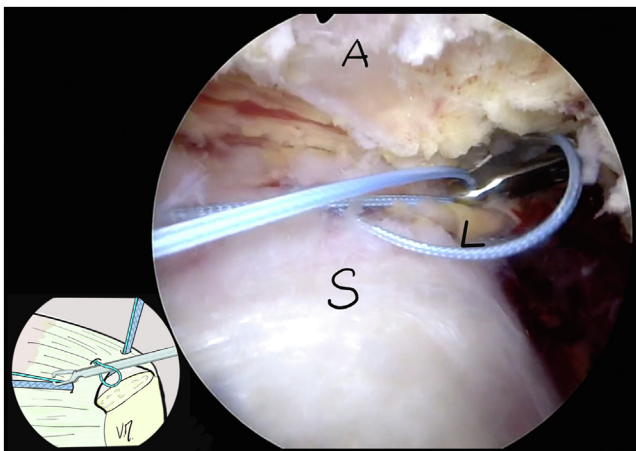


Fig 4. View through the lateral portal of a left shoulder. Patient is in the lateral decubitus position. The length of the central loop (L) is adjusted and the suture retriever recovers the anterior end of the looped suture passing from above to below in the loop. (A, acromion; S, supraspinatus tendon.)

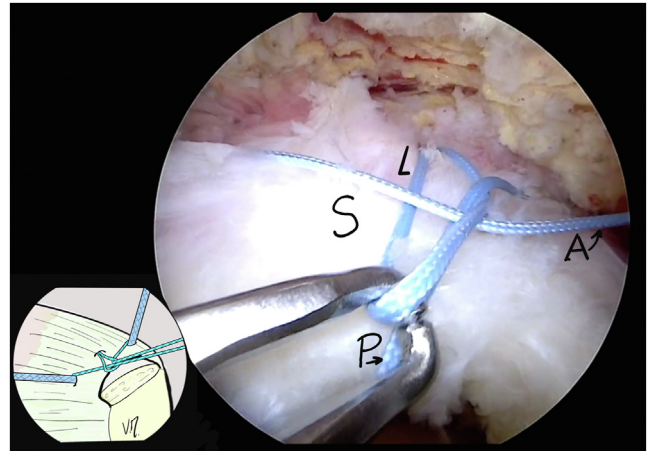


Fig 5. View through the lateral portal of a left shoulder. The patient is in the lateral decubitus position. The anterior end of the suture (A) exits through the posterior portal, and the posterior end (P) from the anterior portal after having crossed the loop (L) from below to above. The length of the loop is adjusted with the help of a suture retriever. (S, supraspinatus tendon.)

Once these adjustments have been made, the anchor is screwed in order to obtain interference between bone, sutures, and anchor as well as obtain a stable repair (Fig 8). The ends of the sutures are cut. It is possible, if necessary, to readjust the tension in the tendon by heat using an electrocoagulation probe.

Postoperative Care

The patient is immobilized in a sling in internal rotation for 4 weeks night and day while performing physical therapy exercises on his/her own, including

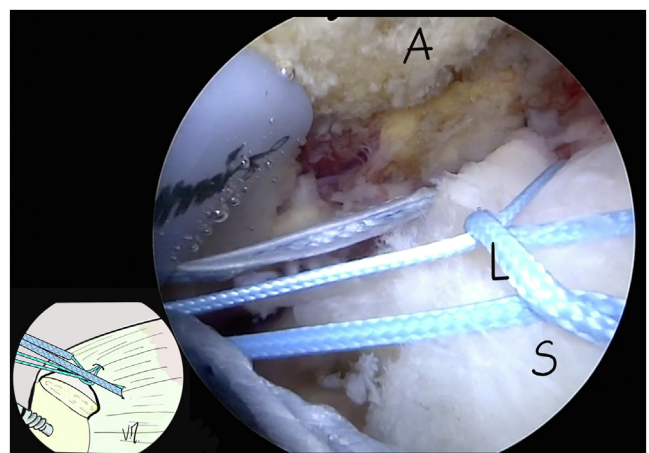


Fig 6. View through the posterior portal of a left shoulder. Patient is in the lateral decubitus position. The 2 ends of the suture and the tape are passed through the lateral portal. Tension is placed on the 4 strands to evaluate the position of the loop (L) and repair the supraspinatus tear (S). (A, acromion.)

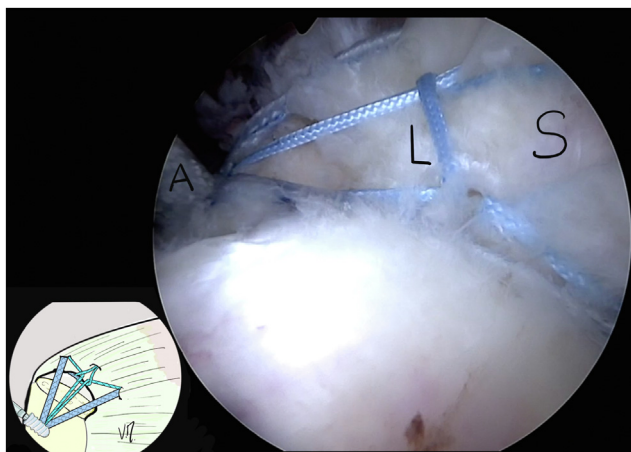


Fig 7. View through the posterior portal of a left shoulder. Patient is in the lateral decubitus position. The 4 strands are passed through an anchor Fixit 5.5mm (SBM) (A), which is screwed into the lateral side of the greater tuberosity after having tightened the tape and the looped suture. The loop (L) is tightened between the ends of the looped suture providing additional contact with the superficial surface of the supraspinatus tendon (S).

active scapulothoracic mobilization and passive glenohumeral mobilization beginning the day after surgery, as well as sessions with a physiotherapist 3 times a week.

Discussion

Double-row repair is the gold standard in the treatment of rotator cuff tears.⁵ Their use is clearly indicated in large supraspinatus tears, especially Collin's classification type D tears that extend to the infraspinatus (Table 3).⁶

Nevertheless, at a time when certain authors are evaluating the environmental impact of surgical

procedures, the indication for this technique in isolated supraspinatus tears, with no associated extension is a subject of debate.^{7,8} Tension band techniques are an interesting option to treat these small tears.^{3,9,10}

When preloaded suture anchors are used, knots must be made near the anchors. This can be difficult on the lateral side of the greater tuberosity because the knot must be tightened and the tear repaired at the same time. Knotless anchors make it possible to first adjust the tension then stabilize the repair by screwing in the suture anchor. Repair solidity is ensured by bone–suture anchor interference fit screw fixation, and the tape stabilizes this.¹¹

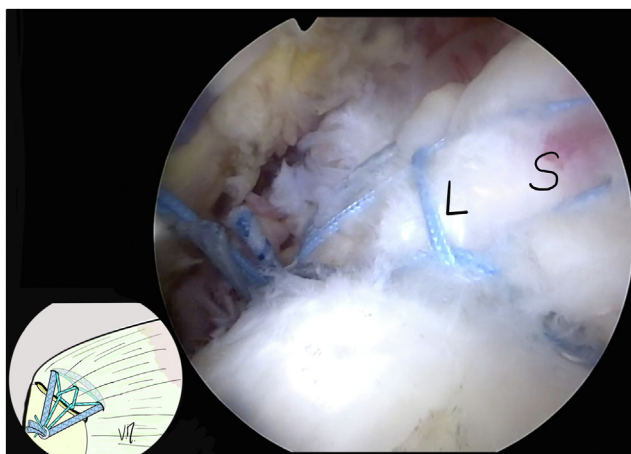




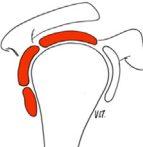


Fig 8. View through the posterior portal of a left shoulder, on patient is in the lateral decubitus position showing the final repair after cutting the ends of the tape and the looped suture. The central loop (L) ensures additional contact with the superficial supraspinatus (S).

Table 3. Collin's Classification: Rotator Cuff Tears Are Classified by the Involved Components

Type	Description	Illustration
A	Supraspinatus and superior subscapularis tear	
B	Supraspinatus and entire subscapularis tear	
C	Supraspinatus, superior subscapularis, and infraspinatus tear	
D	Supraspinatus and infraspinatus tear	
E	Supraspinatus, infraspinatus, and teres minor tear	

The specificity of the Zipknot technique is that it penetrates and attaches the rotator cuff in 3 places with 5 contact points for the sutures on the superficial surface of the tendon. This is possible thanks to the central suture, which makes a lark's head knot, well-known to sailors and mountain climbers. This markedly reduces the risk of a dog ear deformity and also increases the contact between the deep tendon and the greater tuberosity.

This technique reduces the cost of the procedure by limiting the surgical time and only using one anchor. The carbon footprint is also affected: van Egmond et al.¹² used the notion of the 5Rs to limit the carbon footprint of surgeries: refuse (single use), reduce, reusable, repurpose, recycle. A reusable screwdriver is one of the instruments for this procedure.

Making reasonable changes in our practices such as reducing the number of suture anchors per patient should not be associated with a risk of failure due to incomplete healing as the Hybrid criteria are considered (Fig. 9).⁷ Thus, patients should be nonsmokers, without hypercholesterolemia, and the muscular fatty infiltration index should be less than 2 (Table 4).^{9,13}

Conclusions

The Zipknot technique is a procedure to repair isolated supraspinatus tears. There is a relatively short learning curve. At a time when the carbon footprint of surgeries is an issue, this is a reliable and economical option using a single anchor.

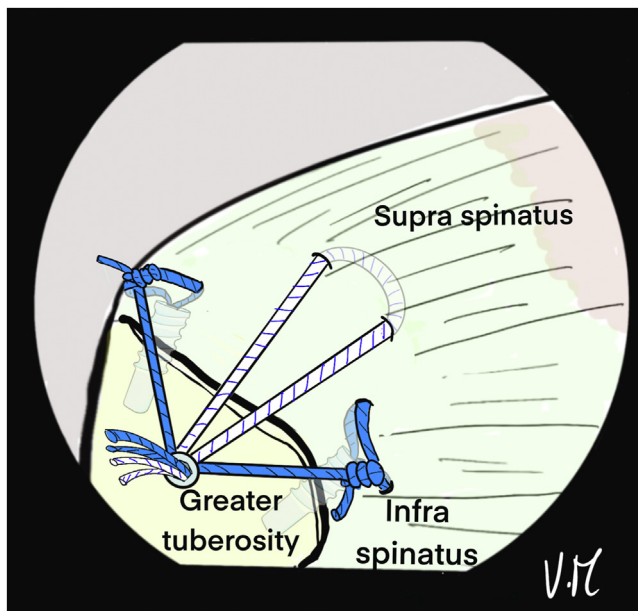


Fig 9. Illustration of an arthroscopic subacromial view from posterior portal in beach chair position on a left shoulder, showing final aspect with Hybridge technique⁷: It combines a central knotless tensile band and a peripheral suture bridge with only 3 anchors.

Table 4. Fatty Infiltration Index Classification of Goutallier: Measurement of Fat in Rotator Cuff Muscles on Preoperative MRI

Grade	Amount of Fat in Muscles
Grade 0	Normal muscle
Grade 1	Muscle contains some fatty steaks
Grade 2	Fatty infiltration, but still more muscle than fat
Grade 3	Equal amounts of fatty infiltration and muscle
Grade 4	More fatty infiltration than muscle is present

MRI, magnetic resonance imaging.

References

1. Ponugoti N, Raghu A, Colaco HB, Magill H. A comparison of simple and complex single-row versus transosseous-equivalent double-row repair techniques for full-thickness rotator cuff tears: A systematic review and meta-analysis. *JSES Int* 2021;6:70-78.
2. Rabin AS, Pinsky EG. Reducing health care's climate impact—mission critical or extra credit? *N Engl J Med* 2023;389:583-585.
3. Boileau P, Brassart N, Watkinson DJ, Carles M, Hatzidakis AM, Krishnan SG. Arthroscopic repair of full-thickness tears of the supraspinatus: Does the tendon really heal? *J Bone Joint Surg Am* 2005;87:1229-1240.
4. Bae KH, Kim JW, Kim TK, et al. Is the arthroscopic modified tension band suture technique suitable for all full-thickness rotator cuff tears? *J Shoulder Elbow Surg* 2016;25:1457-1463.
5. Imam M, Sallam A, Ernstbrunner L, et al. Three-year functional outcome of transosseous-equivalent double-row vs. single-row repair of small and large rotator cuff tears: A double-blinded randomized controlled trial. *J Shoulder Elbow Surg* 2020;29:2015-2026.
6. Collin P, Matsumura N, Lädermann A, Denard PJ, Walch G. Relationship between massive chronic rotator cuff tear pattern and loss of active shoulder range of motion. *J Shoulder Elbow Surg* 2014;23:1195-1202.
7. Martinel V, Nourissat G, Barth J, Zipoli B, Bonneville N. Green Shoulder Circle. The Hybridge technique: A combined technique of suture bridge and tension band for an arthroscopic eco-responsible rotator cuff repair. *Arthrosc Tech* 2022;11:e2337-e2345.
8. Dzau VJ, Levine R, Barrett G, Witty A. Decarbonizing the U.S. health sector—a call to action. *N Engl J Med* 2021;385:2117-2119.
9. Schanda JE, Eigenschink M, Laky B, et al. Rotator cuff delamination is associated with increased tendon retraction and higher fatty muscle infiltration: A comparative study on arthroscopy and magnetic resonance imaging. *Arthroscopy* 2022;38:2131-2141.e1.
10. Elkins A, Lam PH, Murrell GAC. A novel, fast, safe, and effective all-inside arthroscopic rotator cuff repair technique: Results of 1000 consecutive cases. *Orthop J Sports Med* 2019;7:2325967119864088.
11. Liu RW, Lam PH, Shepherd HM, Murrell GAC. Tape versus suture in arthroscopic rotator cuff repair: Biomechanical analysis and assessment of failure rates at 6 months. *Orthop J Sports Med* 2017;5:2325967117701212.
12. van Egmond PWP, Meester RJR, van Dijk CNN. From big hands to green fingers: It is time for a change. *J ISAKOS* 2023;8:213-215.
13. Danilkowicz R, Levin JM, Crook B, Long JS, Vap A. Analysis of risk factors, complications, reoperations, and demographics associated with open and arthroscopic rotator cuff repair: An analysis of a large national database. *Arthroscopy* 2022;38:737-742.