

## Technical Note

# The Mirror Anterolateral Ligament: A Simple Technique to Reconstruct the Deep Medial Collateral Ligament Using the Gracilis Associated With a Four-Strand Semitendinosus for Anterior Cruciate Ligament Reconstruction

Jérémy Daxhelet, M.D., Nicolas Bouguennec, M.D., and Nicolas Gravelleau, M.D.

**Abstract:** We present a surgical technique to reconstruct the deep portion of the medial collateral ligament (MCL) when associated with an injury of the anterior cruciate ligament (ACL). Patients could benefit from this procedure in cases of ACL reconstruction and persistent laxity at 20° of flexion of the MCL without any laxity in extension. This surgery uses the gracilis to reconstruct the deep portion of the MCL in the same manner described for the anterolateral ligament on the other side of the knee. The procedure is performed percutaneously, graft and tunnels are independent from the ACL, a screw is used on the femoral side, and a cortical device is used on the tibial side.

Anterior cruciate ligament (ACL) ruptures often are associated with medial collateral ligament (MCL) injuries, as injuries of the MCL complex on magnetic resonance imaging (MRI) are observed in 67% of patients with ACL rupture.<sup>1</sup> Despite excellent spontaneous healing of the MCL, controversy exists regarding the optimal treatment of concomitant MCL-ACL ruptures. Greater re-rupture rate after ACL reconstruction without addressing a potential MCL lesion has been described,<sup>2</sup> and many papers recommend a more specific analysis and treatment for medial knee injuries.<sup>3</sup> Debate exists about the exact role of each medial and posteromedial structure. Some recent techniques have aimed to reconstruct the superficial part of the MCL.<sup>4</sup>

However, specific injury of the deep portion of the medial collateral ligament (dMCL) is associated with

persistent pain and disability<sup>5</sup> and greater risk of ramp lesion in acute settings when associated with ACL tear.<sup>1</sup> Furthermore, the dMCL plays a major role in restraining the anteromedial rotatory instability (AMRI) by limiting external rotation in full extension.<sup>6</sup> Those observations advocate for a specific reconstruction procedure of the dMCL with ACL rupture and pathologic laxity.

We describe a technique inspired by a previously described technique for combined reconstruction of ACL<sup>7</sup> and the anterolateral ligament (ALL) (Fig 1), mimicking, but in a mirror manner, the ALL reconstruction on the contralateral side of the knee. This simple technique allows one to use the same devices and instruments and to only change the knee side for the peripheral procedure (Video 1). This technique doesn't apply to patients who require posteromedial reconstruction. The main advantages and disadvantages of this technique can be found in Table 1.

## Surgical Technique (With Video Illustration)

The patient is operated under spinal or general anesthesia combined with locoregional anesthesia to control postoperative pain. He or she is placed in supine position, and an air tourniquet is applied to the limb with a pressure of 300 mm Hg. The 2 tendons (semitendinosus and gracilis) are harvested using a tendon harvester (ConMed Linvatec, Largo, FL).

*From the Sports Clinic of Bordeaux-Mérignac, Mérignac, France.*

*The authors report that they have no conflicts of interest in the authorship and publication of this article. Full ICMJE author disclosure forms are available for this article online, as [supplementary material](#).*

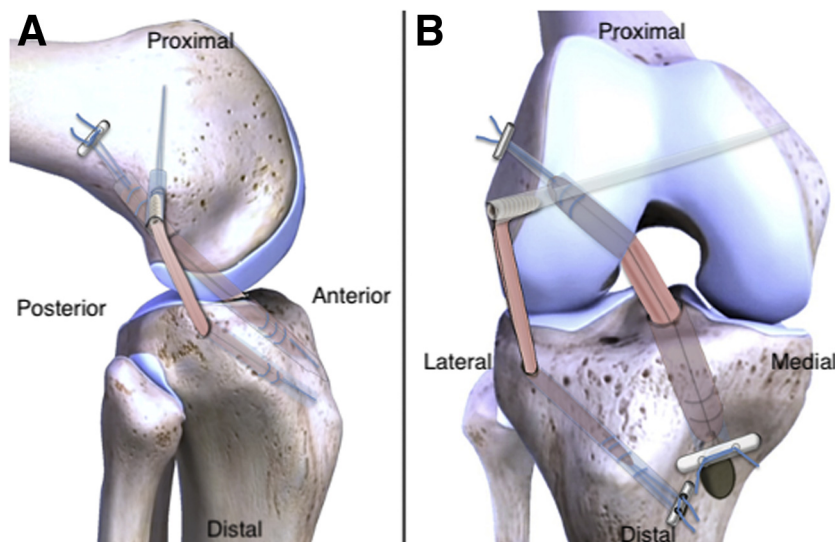
*Received January 18, 2022; accepted March 13, 2022.*

*Address correspondence to Nicolas Bouguennec, Clinique du Sport, 2 rue Nègrevergne, 33700 Mérignac, France. E-mail: [nbouguennec@gmail.com](mailto:nbouguennec@gmail.com)*

*© 2022 THE AUTHORS. Published by Elsevier Inc. on behalf of the Arthroscopy Association of North America. This is an open access article under the CC BY-NC-ND license (<http://creativecommons.org/licenses/by-nc-nd/4.0/>).*

2212-6287/22123

<https://doi.org/10.1016/j.eats.2022.03.030>



**Fig 1.** Illustration of the initial technique for combined anterior cruciate ligament and anterolateral ligament reconstruction.

**Table 1.** Advantages and Disadvantages

| Advantages  | Disadvantages  |
|---|--|
| Fast and simple procedure   | Technique for deep portion of the medial collateral ligament reconstruction only |
| No supplementary instrumentation or implants required   | Concerns laxity at 20° of flexion without laxity in extension                    |
| Using the gracilis allows the surgeon to perform a 4-strand semitendinosus graft for the anterior cruciate ligament |  |
| Percutaneous technique  |  |

### Preparation of the Grafts

The ACL graft is prepared using the semitendinosus in 4 strands. Two cortical suspensory adjustable devices are used, with a standard Pullup (SBM, Lourdes, France) adjustable device on the femoral side and a Pullup XL (SBM, Lourdes, France) adjustable device on the tibial side.

For the MCL graft, the gracilis is folded on a Tight-Rope (Arthrex, Naples, FL). The 2 free strands are then sutured with a FiberLoop 2 (Arthrex), allowing one to apply traction during the procedure with resistant braids. The length of the graft has to be measured and checked for each patient, as the length of the MCL is variable (Fig 2). The diameter is usually between 5 and 6 mm. Both grafts are placed in a gauze sponge with vancomycin.

### Preparation of the ACL Tunnels

The arthroscopic procedure is performed as an isolated ACL reconstruction with a classic anterolateral portal for the arthroscope and an anteromedial portal for the instruments. The apex of the deep cartilage and the capsular line reference are identified to place the entry point for the femoral tunnel at the I.D.E.A.L. (refers to placing a femoral tunnel in a position that reproduces the Isometry of the native ACL, that covers

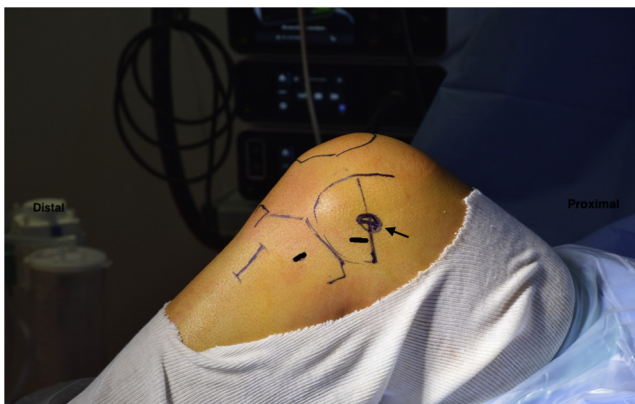the fibers of the Direct insertion histologically, that is Eccentrically located in the anterior (high) and proximal (deep) region of the footprint, that is Anatomical (within the footprint), and that replicates the Low tension-flexion pattern of the native ACL throughout the range of flexion and extension) position.<sup>8</sup> The femoral socket is prepared. The tibial tunnel is then performed with a joint aperture at the center of the native footprint.

### MCL Femoral Preparation

Identification of the landmarks is performed (Fig 3). According to the literature, the femoral insertion is 6 mm distal and 5 mm posterior to the medial epicondyle. The femoral tunnel is performed with a 4.5-mm drill or a k-wire targeting anteriorly and proximally and then drilled at the measured diameter of the MCL graft. Visualization of the femoral ACL tunnel with "tunneloscopy" is recommended to avoid tunnel convergence (Fig 4). The MCL graft is pulled in the femoral tunnel and is fixed using a bioabsorbable screw with a diameter superior of 1 mm relative to the graft as the bone of the medial femoral condyle is less resistant than the lateral condyle. Usually, a 6 × 230-mm bioabsorbable screw (Arthrex) is used (Fig 5).



**Fig 2.** Deep portion of the medial collateral ligament graft preparation using the gracilis folded on a suspensory device (for the tibial fixation) and a traction suture on the other side (for the femoral socket).

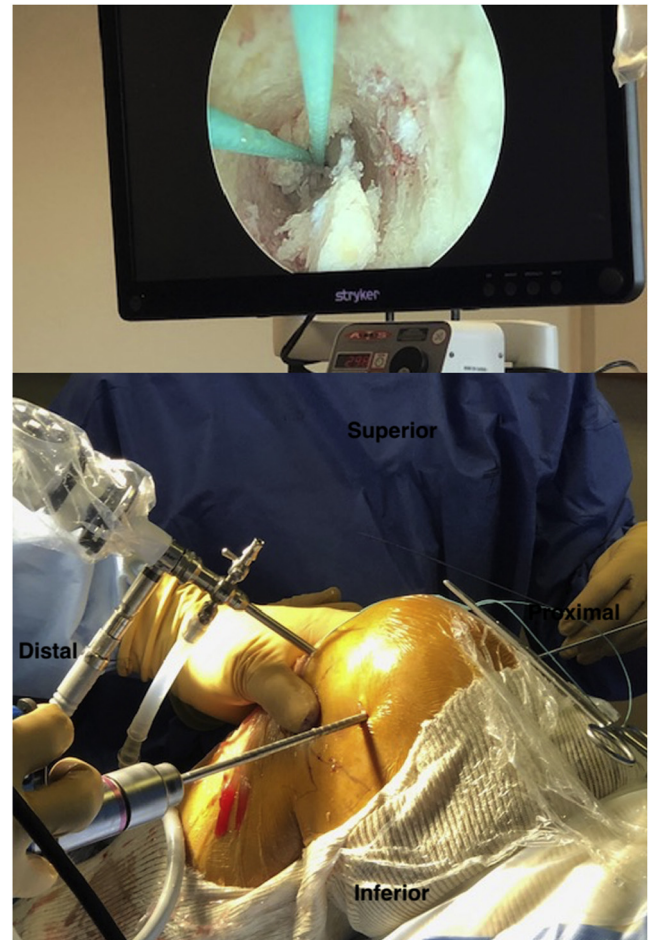


**Fig 3.** Landmarks for the deep portion of the medial collateral ligament (dMCL) graft on the medial side of the knee showing the femoral and tibial insertions of the deep MCL (black lines) and the medial epicondyle (black arrow).

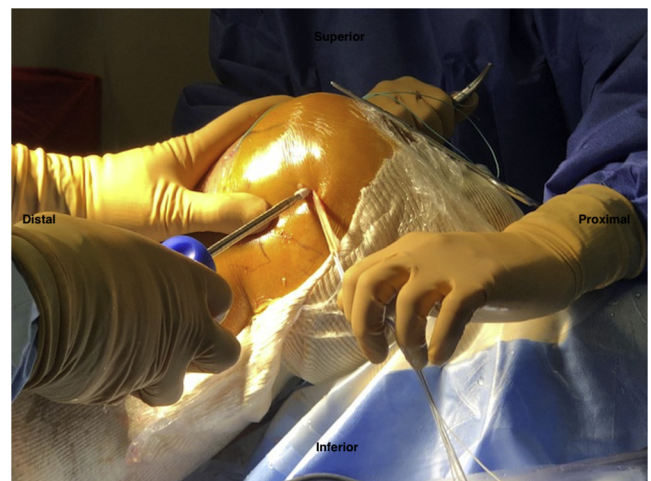### MCL Tibial Preparation

On the tibial side, the dMCL spreads to an area located 8 mm distal to the joint line and between 17 and 39 mm (33%-76%) anteroposteriorly.<sup>9</sup> We recommend to check the graft length and isometry before creating the tunnels.

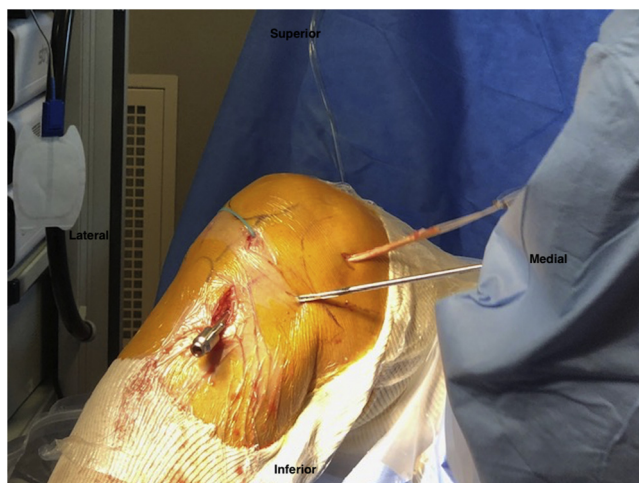
The tibial aimer of the ACL reconstruction at 70° position is placed on the tibial entry point targeting the



**Fig 4.** Drilling the femoral tunnel of the deep portion of the medial collateral ligament on the medial side of the knee under direct visualization of the anterior cruciate ligament femoral tunnel to avoid tunnels convergence.



**Fig 5.** Femoral fixation of the deep portion of the medial collateral ligament graft on the medial side of the knee with a screw.



**Fig 6.** Performing the tibial tunnel of the deep portion of the medial collateral on the medial side of the knee with a 4.5-mm drill bit. A cannula is placed in the anterior cruciate ligament tunnel to avoid tunnel convergence.

lateral tibial cortex. This also can be performed in a free-hand technique. The tibial tunnel is created with the 4.5-mm drill and then with a drill at the measured diameter without issuing the lateral tibial cortex as a cortical device is used. A cannula is concomitantly placed in the tibial ACL tunnel to ensure that both tibial tunnels are not convergent (Fig 6). We recommend placing the tibial tunnel for the MCL posteriorly to the ACL tibial tunnel.

The graft is passed under the aponeurosis and is then pulled in the tibial tunnel (Fig 7). The ACL graft is passed from the tibial side to the femoral side and cortical devices are tightened. The tibial cortical device of the MCL graft is finally tightened at 30° of flexion. Intra-articular checking is undertaken to ensure the ACL graft is tightened and that there's no conflict with the notch. Particular attention is recommended to avoid interposition of muscle or aponeurosis when tightening the cortical fixation of the MCL (Fig 8). Surgical pearls and pitfalls can be found in Table 2.

## Postoperative Rehabilitation

The rehabilitation protocol remains the same as an isolated ACL reconstruction. We do not systematically use braces. Immediate weight-bearing and unrestricted progressive range of motion are authorized.

## Discussion

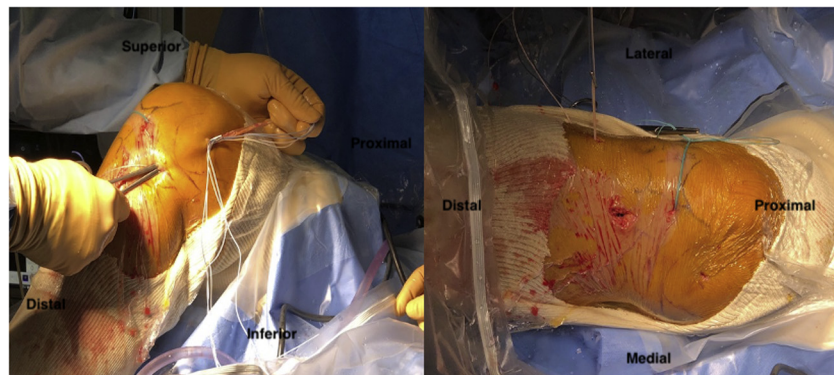
We present a simple technique to reconstruct the deep MCL in patient suffering from medial insufficiency concomitant to ACL rupture with laxity at 20° of flexion without any laxity in extension. It is consistent with recent papers highlighting the role of the medial structures, especially restraining the AMRI.

This concept can be simply understood by mirroring the theory of the ALL reconstruction on the contralateral side. We extended this simplification going from theory to practice and decided to mimic a previously described ALL reconstruction on the medial side. This way simplifies the intervention for the team and nurses and allows to adapt the reconstruction peroperatively if necessary.

The medial side of the knee is the most frequently injured and is historically known to positively respond to conservative treatment.<sup>9,10</sup> However, there is an existing controversy regarding how surgeons address those lesions, especially when they are associated with ACL tears.<sup>9,11,12</sup> Willinger et al.<sup>1</sup> recently have shown that 67% of patients presenting with an ACL rupture had a concomitant medial injury on the MRI scan. Those MCL lesions and laxity are a recognized risk factor for ACL re-rupture in case of isolated ACL reconstruction.<sup>2,13</sup>

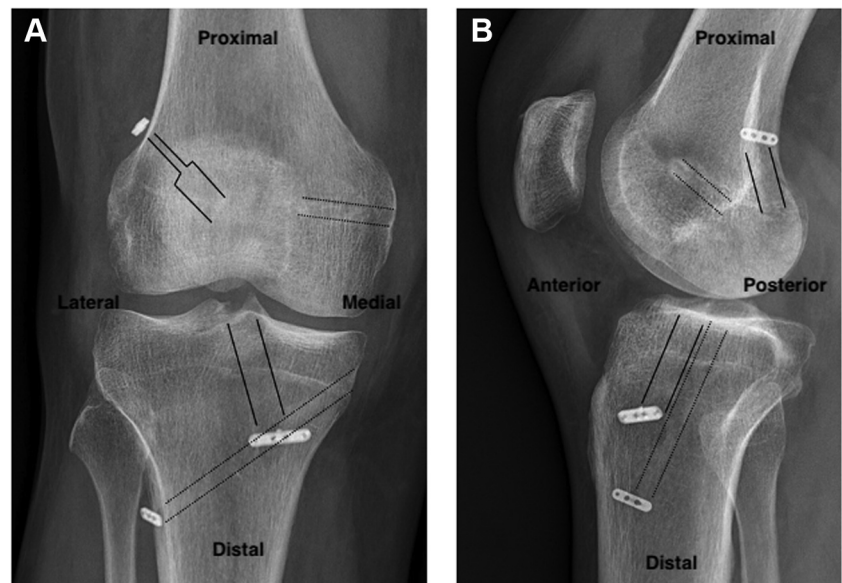
The exact function of each medial and posteromedial structure has still to be clarified. A better understanding of their action on knee rotational stability will certainly modify the way we treat concomitant medial and ACL lesions in the coming years. However, the dMCL seems to play a major role in the field of medial side injuries and AMRI.

In 2010, Narvani et al.<sup>5</sup> identified a population suffering from pain and disability after specific lesioning



**Fig 7.** Passing the deep portion of the medial collateral under the fascia (from the femur to the medial side of the tibia) and then in the tibial tunnel with the button exiting the tibial tunnel on the lateral side of the knee.

**Fig 8.** (A) Anteroposterior and (B) profile postoperative radiographs of a right knee with anterior cruciate ligament (ACL) reconstruction and a “mirror anterolateral ligament” technique for the deep portion of the medial collateral ligament (dMCL) (continuous lines correspond to ACL tunnels and dotted lines correspond to the dMCL).



**Table 2.** Surgical Pearls and Pitfalls

| Pearls   | Pitfalls  |
|--|---|
| Check the length and isometry of the graft before drilling the tunnels                                   | Anisometric position with percutaneous position can lead to failure of the dMCL graft                       |
| Performing the femoral tunnel in a free hand technique is easier   | Avoid convergence of femoral tunnels performing the dMCL femoral tunnel targeting proximally and anteriorly |
| The tibial tunnel of the dMCL should be posterior to the tibial tunnel of the anterior cruciate ligament | Convergence of the tibial tunnels if the dMCL tibial tunnel is too anterior                                 |
| Check that the cortical fixation is applied on the tibial cortex   | Avoid interposition of the aponeurosis or muscle when tightening the dMCL tibial fixation                   |

dMCL, deep portion of the medial collateral ligament.

of this structure. Its anatomy has recently been described by Athwal et al.<sup>14</sup> and provides a specific restrain to tibial external rotation, confirmed by the work of Ball et al.<sup>6</sup> Its impact on tibial rotational laxity also has been described in the field of knee arthroplasty.<sup>15</sup> Furthermore, MRI studies described an association between dMCL lesion and ramp lesion.<sup>1</sup>

There is therefore a trend in the literature supporting the need for dMCL reconstruction aiming to improve stability in case of medial and/or rotational laxity associated with ACL rupture.<sup>16</sup>

This current theory can be compared with the role of ALL reconstruction, which had entirely changed the way surgeons analyze and addresses lateral rotational instability.

Extending this reflection and the need to reconstruct a so-called “anteromedial ligament,”<sup>6,14</sup> we translated a previous technique for the ALL reconstruction to the medial side of the knee. Our algorithm of treatment for such lesions is based on a first critical clinical evaluation. A positive valgus test in extension and 20° of

flexion leads us to consider an open repair or reconstruction of MCL and posteromedial corner. Further studies are required to better evaluate its impact on rotational stability and identify patients who could benefit from this type of reconstruction.

## References

1. Willinger L, Balendra G, Pai V, et al. High incidence of superficial and deep medial collateral ligament injuries in “isolated” anterior cruciate ligament ruptures: A long overlooked injury. *Knee Surg Sports Traumatol Arthrosc* 2022;30:167-175.
2. Alm L, Krause M, Frosch KH, Akoto R. Preoperative medial knee instability is an underestimated risk factor for failure of revision ACL reconstruction. *Knee Surg Sports Traumatol Arthrosc* 2020;28:2458-2467.
3. Chahla J, Kunze KN, LaPrade RF, et al. The posteromedial corner of the knee: An international expert consensus statement on diagnosis, classification, treatment, and rehabilitation. *Knee Surg Sports Traumatol Arthrosc* 2021;29:2976-2986.

4. Watson ST, Pichiotino ER, Adams JD. Medial collateral ligament reconstruction with dual adjustable-loop suspensory fixation: A technique guide. *Arthrosc Tech* 2021;10:e621-e628.
5. Narvani A, Mahmud T, Lavelle J, Williams A. Injury to the proximal deep medial collateral ligament: A problematical subgroup of injuries. *J Bone Joint Surg Br* 2010;92:949-953.
6. Ball S, Stephen JM, El-Daou H, Williams A, Amis AA. The medial ligaments and the ACL restrain anteromedial laxity of the knee. *Knee Surg Sports Traumatol Arthrosc* 2020;28:3700-3708.
7. Colombet P, Graveleau N. An anterior cruciate ligament reconstruction technique with 4-strand semitendinosus grafts, using outside-in tibial tunnel drilling and suspensory fixation devices. *Arthrosc Tech* 2015;4:e507-e511.
8. Colombet P, Silvestre A, Bouguennec N. The capsular line reference, a new arthroscopic reference for posterior/anterior femoral tunnel positioning in anterior cruciate ligament reconstruction. *J Exp Orthop* 2018;5:9.
9. Fetto JF, Marshall JL. Medial collateral ligament injuries of the knee: A rationale for treatment. *Clin Orthop Relat Res* 1978;132:206-218.
10. Indelicato PA. Non-operative treatment of complete tears of the medial collateral ligament of the knee. *J Bone Joint Surg Am* 1983;65:323-329.
11. Bollier M, Smith P. Anterior cruciate ligament and medial collateral ligament injuries. *J Knee Surg* 2014;27:359-368.
12. Halinen J, Lindahl J, Hirvensalo E, Santavirta S. Operative and nonoperative treatments of medial collateral ligament rupture with early anterior cruciate ligament reconstruction: A prospective randomized study. *Am J Sports Med* 2006;34:1134-1140.
13. Svantesson E, Hamrin Senorski E, Alentorn-Geli E, et al. Increased risk of ACL revision with non-surgical treatment of a concomitant medial collateral ligament injury: A study on 19,457 patients from the Swedish National Knee Ligament Registry. *Knee Surg Sports Traumatol Arthrosc* 2019;27:2450-2459.
14. Athwal KK, Willinger L, Shinohara S, Ball S, Williams A, Amis AA. The bone attachments of the medial collateral and posterior oblique ligaments are defined anatomically and radiographically. *Knee Surg Sports Traumatol Arthrosc* 2020;28:3709-3719.
15. Cavaignac E, Carpentier K, Pailhé R, Luyckx T, Bellemans J. The role of the deep medial collateral ligament in controlling rotational stability of the knee. *Knee Surg Sports Traumatol Arthrosc* 2015;23:3101-3107.
16. Abermann E, Wierer G, Herbort M, Smigielski R, Fink C. MCL reconstruction using a flat tendon graft for anteromedial and posteromedial instability. *Arthrosc Tech* 2022;11:e291-e300.