

## Technical Note

# Large-Diameter Anterior Cruciate Ligament Reconstruction Technique With 8-Strand Semitendinosus and Gracilis Graft

Rimtautas Gudas, M.D., Ph.D., Augustinas Rimkūnas, M.D., and Mantas Staškūnas, M.S.

**Abstract:** Anterior cruciate ligament (ACL) reconstruction using a single 4-strand semitendinosus graft is a popular technique; unfortunately, the size (diameter) of the graft varies between 7 and 9 mm in many cases. The literature reveals that smaller diameter of the graft determines poorer Knee injury and Osteoarthritis Outcome Score sport/recreation functional scores and leads to revision surgery. Our Technical Note describes a method of preparing >10-mm size hamstring autografts in all cases while increasing the strength of fixation and covering as much of the anatomical ACL attachment footprint area as possible. We report an anatomic reconstruction technique of ACL with 8-strand semitendinosus and gracilis grafts fixed with 2 suspensory fixation systems—PULLUP (SBM, Lourdes, France). Combined with a complete tibial tunnel outside-in approach, this technique allows a quick and easy ACL reconstruction with a large diameter of the graft and increased stability of the fixation.

**R**econstruction of anterior cruciate ligament (ACL) is one of the most common surgical procedures in orthopaedics. Operative techniques improve over the years, and better outcomes are achieved. However, the literature reveals up to one-fifth of patients post-ACL reconstruction have less-than-optimal results.<sup>1</sup> One of the causes of failure is ACL grafts that are less than 8 mm in diameter; therefore, it is recommended to use grafts that are larger than 8 mm in diameter.<sup>2,3</sup> In contrast, Wernecke et al.<sup>4</sup> did not find significant correlations between the graft diameter and revision rate or clinical outcomes. Despite conflicting evidence and differences in graft preparation and fixation options, we believe a larger ACL graft is an important factor for achieving better outcomes after ACL

reconstruction. At the same time, the preliminary optimal graft diameter can be predicted according to individual anthropometric details before choosing the right graft-preparation technique.<sup>5</sup>

A widely used grafting technique for ACL reconstruction is anatomic single-bundle 4-strand semitendinosus graft; however, it limits the possibility of obtaining larger ACL grafts and at the same time limits the coverage of ACL footprint area, reducing the strength of fixation and at times is inadequate for the anthropometrically predicted graft size. The developed semitendinosus/gracilis (ST/G) ACL graft-preparation technique has been able to achieve diameters of up to 10 to 13 mm. The described outside-in method uses ENDOBUTTON systems on femoral and tibial tunnels, i.e. the PULLUP standard and XL fixation ENDOBUTTONs (SBM, Lourdes, France), available in 2 sizes. The smaller ENDOBUTTON has to be fixed on a 4.5-mm femoral bone tunnel, whereas the XL ENDOBUTTON is fixed on the tibial canal, as large as 12 mm, or even 13 mm in diameter. We present a quick and easy technique of preparing and fixing large-diameter ACL autografts while increasing the strength and stability of fixation, fulfilling as much of the ACL footprint area as possible, and improving prognostic functional outcomes.

## Surgical Technique (With Video Illustration)

This technique is similar to an already-published technique.<sup>6</sup> While both techniques use suspensory

*From the Department of Orthopedics and Traumatology, Hospital of Lithuanian University of Health Sciences (LSMU), Kaunas Clinics, Kaunas, Lithuania.*

*The authors report that they have no conflicts of interest in the authorship and publication of this article. Full ICMJE author disclosure forms are available for this article online, as [supplementary material](#).*

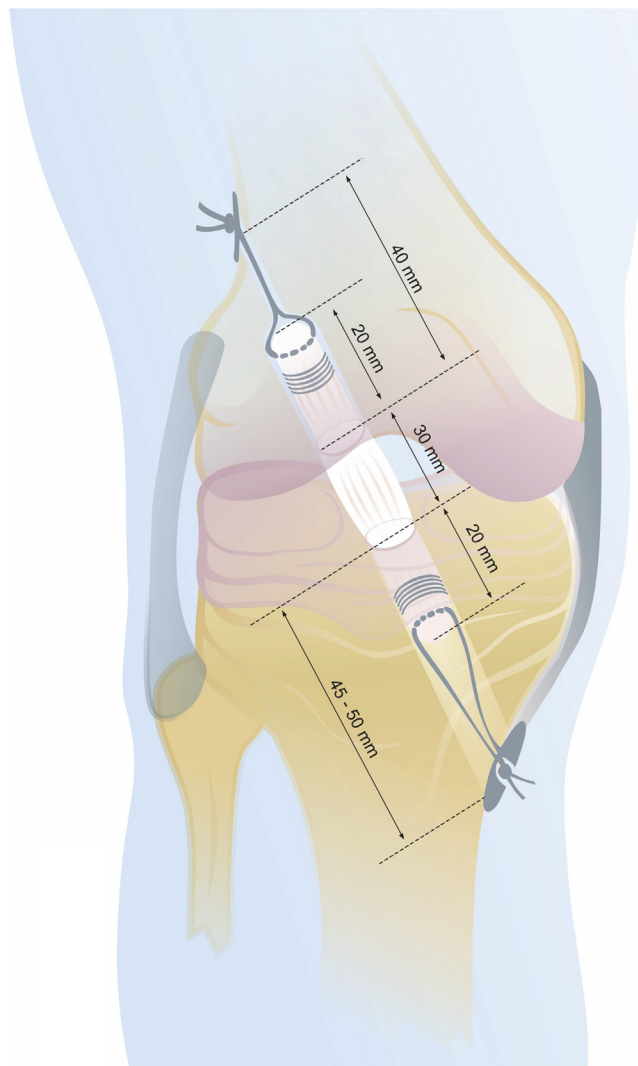
*Received September 7, 2020; accepted November 16, 2020.*

*Address correspondence to Rimtautas Gudas, Department of Orthopaedics and Traumatology, The Hospital of Lithuanian University of Health Sciences (LSMU), Kaunas Clinics, Eivenių g. 2., LT-50162, Kaunas, Lithuania. E-mail: [rimitautasrimtautas.rr@gmail.lt](mailto:rimitautasrimtautas.rr@gmail.lt)*

*© 2020 by the Arthroscopy Association of North America. Published by Elsevier. This is an open access article under the CC BY-NC-ND license (<http://creativecommons.org/licenses/by-nc-nd/4.0/>).*

*2212-6287/201529*

*<https://doi.org/10.1016/j.eats.2020.11.020>*



**Fig 1.** Illustration of the final graft reconstruction using outside-in ACL reconstruction technique with adjustable suspensory fixation on both femoral and tibial sides: PULLUP and PULLUP XL fixation systems (SBM, Lourdes, France). Graft length for the 8-strand ST/G technique is 7 cm: 2 cm within the femoral socket, about 3 cm in the knee joint space, and 2 cm within the tibial tunnel. (ACL, anterior cruciate ligament; ST/G, semitendinosus/gracilis.)

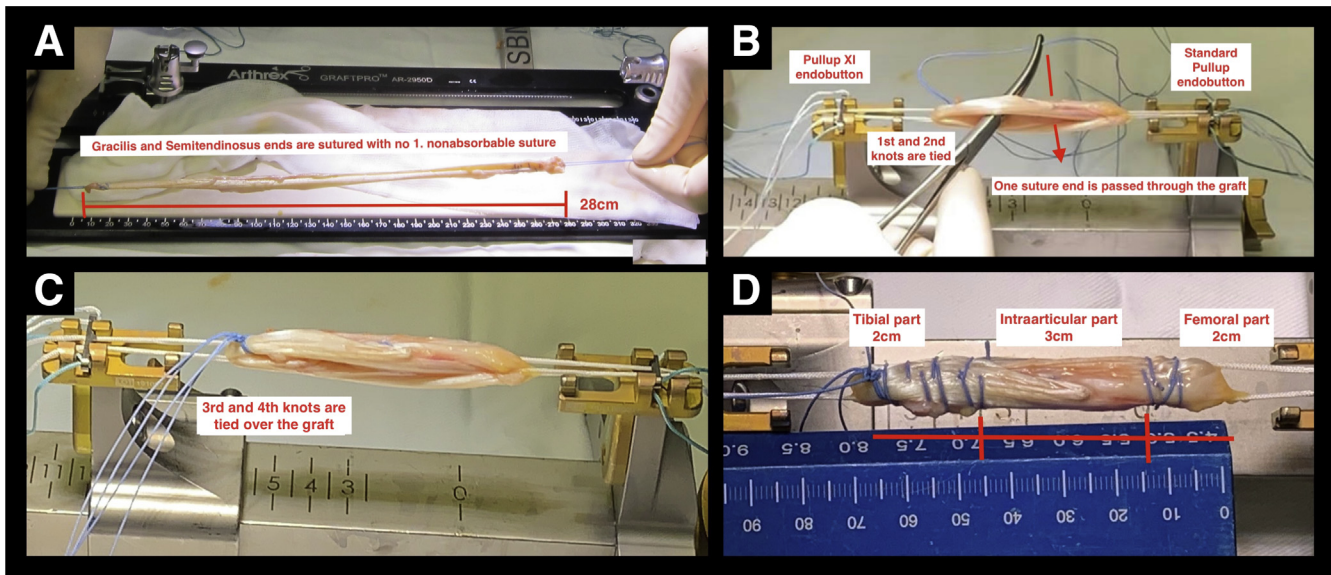
fixation at the femoral and tibial sides, we also use both semitendinosus and gracilis tendons. Calculations on how to predict ST graft length based on patient height already have been described.<sup>7</sup> The optimal graft length for the 8-strand ST/G technique is 28 cm and at least 7 cm after folding: 20 mm in the femoral bone socket, about 30 mm intra-articular and 20 mm in the tibial canal (Fig 1).

Semitendinosus and gracilis full-length tendons are harvested using standard technique, trimmed to 28 cm in length, and sutured at the ends with a no. 1 nonabsorbable suture (Video 1 and Fig 2A) It is best not to separate the tendon tibial attachment while harvesting and cut it out in one unit.

Both tendons are passed through the suture loop of PULLUP XL system and bent, achieving a 4-strand ST/G

14-mm graft. The sutured ends of the graft are passed through the loop of smaller PULLUP system, bent, and tensed. One suture end is passed through the loop of XL PULLUP system and sutures are tied twice; again, one suture end is passed between the strands of the graft (Fig 2B) and tied twice at the tibial end, already achieving a stable graft construct and making it easier to suture final graft ends (Fig 2C) An 8-strand final graft, measured from 10 to 13 mm in all cases, is obtained (Fig 2D).

It is important to measure the diameter of the 8-strand ST/G autograft is even over the length of the graft. A final 8-strand graft, approximately 60 to 75 mm in length, is obtained (Fig 2D). Exactly 70 mm of length was used in the presented case. After preparation, the graft is tensed and locked in tension with the GraftTech table (SBM) until implantation. The diameter of the



**Fig 2.** Graft-preparation technique. (A) Semitendinosus and gracilis grafts of 28 cm length are sutured together at the ends with no. 1 nonabsorbable suture. One suture end (graft end) is passed through the suture loop of PULLUP XL system and bent twice to 2 even parts. Both of those parts are passed through the suture loop of standard PULLUP ENDOBUTTON suture and tensed. (B) One suture end is passed through the loop of XL PULLUP system and tied over the suture loop twice, achieving an already stable graft construct. (B) One suture end is passed through the strands of the graft to tie the third and fourth knots. (C) The third and fourth knots are tied over the graft, achieving a solid graft construct before suturing graft ends. (D) Femoral and tibial sides (ends of the graft) are sutured again with no. 1 nonabsorbable suture up to 2 cm. It is best to leave the intra-articular part of the graft suture free.

prepared graft is always between 10 and 13 mm. In this particular case, it was 11 mm.

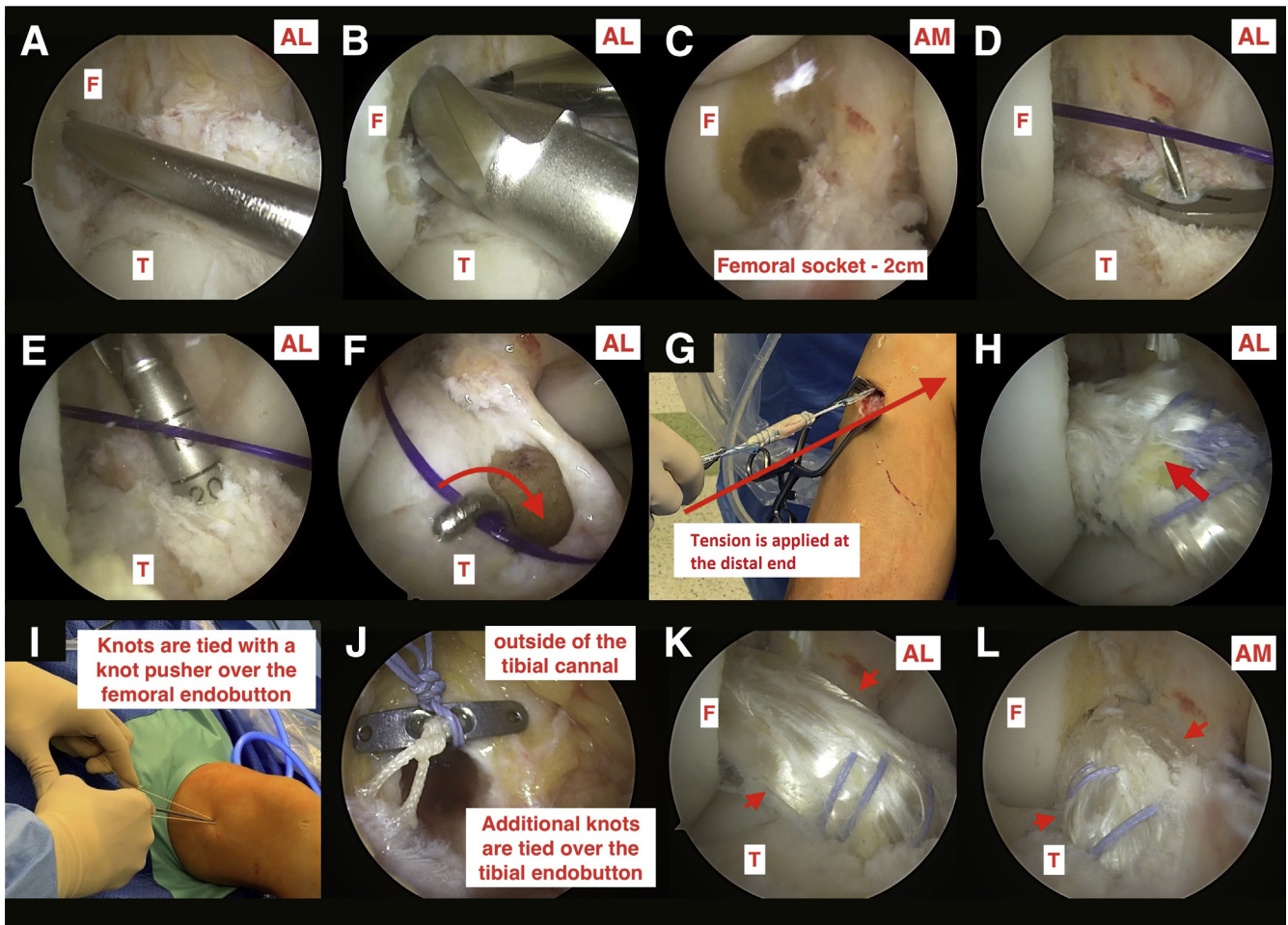
Standard anterolateral and anteromedial portals are used for arthroscopy and an accessory anteromedial portal for instrumentation. Debridement, menisci surgery, and visualization of the intercondylar notch are performed before ACL reconstruction. The femoral canal is established in the direction from intra-articularly to outside. A full 4.5-mm bone canal is formed with a specialized drill while the knee is fully flexed (Fig 3A). Then, a femoral socket is reamed, gradually increasing the diameter of the drill until it becomes equal to the graft (Fig 3B). A socket length of a 20 mm is recommended (Fig 3C). Sutures are passed through the femoral tunnel. Then, a full tibial tunnel is drilled using an outside-in approach using a tibial aimer set from 60 to 65° to obtain a long-enough bone tunnel calibrated with the length and width of the graft (Fig 3D and E). The length of the tunnel from 45 to 50 mm is recommended. Intra-articular tunnel sharp edges are burred to decrease the possible damage to the graft. Sutures are retrieved through the tibial tunnel (Fig 3F) and the graft is loaded (Fig 3G). The graft is pulled outside-in and tracked with a scope as it moves through the joint space to the femoral socket, at the same time carefully tracing as the graft locks on the femoral bone cortex (Fig 3H). To ensure that the ENDOBUTTON has exited the canal and flipped, special sutures of the

PULLUP ENDOBUTTON are used. Tensioning threads are used to strain the fixation loops and fix the autograft in the femoral socket. Additional knots are tied over the PULLUP femoral button with a knot pusher (Fig 3I). Tensioning threads are tensed at the tibial end to tighten and lock the graft in place while the knee is in 20° flexion. Additional knots are tied over the PULLUP XL tibial button (Fig 3J). The graft is fixed (Fig 3K and L). Inspection of the intercondylar notch is performed and possible impingement of the ACL graft is checked and a notchplasty is performed if needed.

## Discussion

ACL reconstruction using one 4-strand semitendinosus tendon autograft is becoming a popular surgical approach; it enables one to harvest only the tendon of semitendinosus and minimizes the post-operative weakness of the hamstring muscles.<sup>8</sup> However, as described in the literature, smaller graft diameter accounts for poorer Knee injury and Osteoarthritis Outcome Score function scores; therefore, using only one ST tendon graft is not always optimal. An 8-strand ST/G grafting technique is suggested.

When the diameter of semitendinosus is less than 8 mm for women and 9 mm for men, we harvest both the semitendinosus and gracilis tendons and apply the presented technique. The 8-strand graft with a final diameter between 11 and 13 mm is used while also



**Fig 3.** The patient is in supine position under spinal anesthesia. Outside-in ACL reconstruction technique with adjustable suspensory fixation on both femoral and tibial sides is shown on the right knee. (A) Intra-articular view through the AL portal. A complete 4.5-mm bone tunnel is formed using a special 4.5-mm drill guide in the femoral footprint area of the ACL. (B) Intra-articular view through the AL portal. A 20-mm length femoral socket is drilled over the drill guide of the size, same as the graft, gradually increasing the diameter of the drill from 7 to 11 mm in this particular case. (C) Intra-articular view through the AM portal. Complete femoral tunnel with a socket length of a 20 mm is seen in the femoral ACL footprint area. At this stage, a double PDS suture with a loop is passed through the femoral canal. It is seen as a violet suture in the arthroscopic pictures. (D) Intra-articular view through the AL portal. Full tibial tunnel is drilled using an outside-in approach using a tibial aimer set from 60 to 65° and a special guide. (E) Intra-articular view through the AL portal. Full tibial tunnel is formed, increasing drill sizes gradually to the same diameter as the graft., starting from 7 to 11 mm at this particular case. (F) Intra-articular view through the AL portal. The PDS suture loop are retrieved using an arthroscopic hook into tibial tunnel and out. (G) Extra-articular view of the medial side of the right knee. The free suture ends of femoral side of the graft are passed through the retrieved PDS suture loop (the graft is loaded). As the assistant is pulling the loaded PDS suture at the femoral side, the surgeon applies tension at the distal part of the graft to lock the femoral ENDOBUTTON just as it passes the femoral tunnel. (H) Intra-articular view through the AL portal. The graft is tracked with a scope as it is being pulled from the tibial to the femoral canal and locked. The surgeon pays attention to avoid the graft being stuck or damaged. A lever using arthroscopic probe can be created to achieve smooth graft movement. (I) Extra-articular view of the lateral side of the right knee. Additional knots are tied over the pullup femoral button with a knot pusher. (J) Extra-articular view with a scope at the external part of the tibial canal. Additional knots are tied over the PULLUP XL tibial button. (K) Intra-articular view through the AL portal. The final grafted ACL is shown with arrows. (L) Intra-articular view through the AM portal. The final grafted ACL is shown with arrows. (ACL, anterior cruciate ligament; AL, standard anterolateral portal; AM, standard anteromedial portal; F, medial femoral condyle; PDS, polydioxanone; T, tibial plateau.)

**Table 1.** Advantages and Disadvantages

Advantages	Disadvantages
1. A sufficient diameter graft is obtained if anthropometrical calculations require a diameter of 11 to 13 mm.	1. An additional, bigger suspensory fixation ENDOBUTTON is required.
2. A full-length canal is drilled in the tibia; this different compared with the “all-inside” technique	2. A short graft must be prepared to avoid hypotension of the construct.
3. Increased strength of fixation.	3. Limited availability of 12- to 13-mm size tunnel drills.
4. Greater coverage of the anatomical footprint area.	
5. Suspensory fixation improves graft to bone healing and incorporation.	
6. Complications related to screw fixation are avoided.	
7. Ideal for pediatric ACL reconstruction to avoid growth plate injury.	
8. No need to have different companies screw drivers	

ACL, anterior cruciate ligament.

improving the strength of fixation using only suspensory fixation systems, better prognostic Knee injury and Osteoarthritis Outcome Score values, and increasing footprint coverage compared with one 4-strand ST, 4-strand ST/G grafting, and screw fixation techniques. Graft tensioning using 2 PULLUP system buttons avoids complications related to screw fixation and improves graft healing and incorporation to the bone.<sup>9</sup> At the same time, tibial suspensory fixation allows relative shorter and larger grafting possibilities (Tables 1 and 2).

As variations of autograft dimensions are limited to the surgical method and graft fixing method, we use an outside-in approach. When performing the all-inside technique, an overly long graft during the final tensioning could fold in the tibial socket, resulting in the loosening of the graft.<sup>10</sup> That is why we use, as Colombet and Graveleau<sup>6</sup> recommended, a full tibial canal in the presented outside-in approach. Supplementary interference screw fixation is suggested for cases in which the autograft is overly long and the minimum distance of 5 mm between the distal end of the graft and the tibial cortex (necessary to tense the ENDOBUTTON system on the tibial canal) is not reached.<sup>6</sup>

The limitations of this technique include the limited availability of 12- to 13-mm size tunnel drills in many of orthopaedic sports clinics, hamstring muscle group weakening, and calculating the correct specifications when preparing the graft. The study was approved by Lithuanian University of Health Sciences, Kaunas Clinics ethics committee; patients provided informed consent to participate in the study.

**Table 2.** Pearls and Pitfalls

Pearls	Pitfalls
1. Avoid dividing the ST/G tibial attachment site. We recommend extracting it whole to save time, as you only need to suture the graft at one end.	1. Hold the tibial guide perpendicular to the tibia—do not tilt it up. This is to avoid forming a shorter tibial tunnel and make the graft relatively too long.
2. Shorten the unfolded graft's length to 28 cm to avoid the graft being too long.	2. If the graft is overly long and you do not obtain a 5-mm range between the tibial ENDOBUTTON and the far end of the graft in the tunnel, screw fixation is advised because the tension of the graft is compromised.
3. We recommend using an additional portal superior to the standard anteromedial to ensure visibility during drilling of the femoral tunnel.	3. Length of the graft must not be greater than 65 mm for female patients and 70 mm for male patients; however, it depends on patient's height, i.e. up to 70 mm for taller patients and 60-65 mm for shorter patients.
4. The femoral tunnel should not be longer than 20 mm; the intra-articular graft length is usually 25-30 mm.	4. If an overly long graft is obtained and the tibial tunnel is too short, it is possible to opt for a longer tibial tunnel—up to 25 mm.
5. The tibial aimer should be set to 60-65° to form a long-enough tunnel and to avoid an overly long graft.	
6. Use a burr or shaver to gently smooth the intra-articular tunnel edges to avoid damaging the graft.	

ST/G, semitendinosus/gracilis.

## References

- Galan H, Escalante M, Della Vedova F, Slullitel D. All inside full thickness quadriceps tendon ACL reconstruction: Long term follow up results. *J Exp Orthop* 2020;7:13.
- Snaebjörnsson T, Hamrin Senorski E, et al. Graft diameter as a predictor for revision anterior cruciate ligament reconstruction and KOOS and EQ-5D values: A cohort study from the Swedish National knee ligament Register based on 2240 patients. *Am J Sports Med* 2017;45:2092-2097.
- Figueroa F, Figueroa D, Espregueira-Mendes J. Hamstring autograft size importance in anterior cruciate ligament repair surgery. *EFORT Open Rev* 2018;3:93-97.
- Wernecke GC, Constantinidis A, Harris IA, et al. The diameter of single bundle, hamstring autograft does not significantly influence revision rate or clinical outcomes after anterior cruciate ligament reconstruction. *Knee* 2017;24:1033-1038.
- Ramkumar PN, Hadley MD, Jones MH, Farrow LD. Hamstring autograft in ACL reconstruction: A 13-year predictive analysis of anthropometric factors and

- surgeon trends relating to graft size. *Orthop J Sports Med* 2018;19. 2325967118779788.
6. Colombet P, Graveleau N. An anterior cruciate ligament reconstruction technique with 4-strand semitendinosus grafts, using outside-in tibial tunnel drilling and suspensory fixation devices. *Arthrosc Tech* 2015;4:e507-e511.
  7. Brown JA, Brophy RH, Franco J, et al. Avoiding allograft length mismatch during anterior cruciate ligament reconstruction: Patient height as an indicator of appropriate graft length. *Am J Sports Med* 2007;35: 986-989.
  8. Collette M, Cassard X. The tape locking screw technique (TLS): A new ACL reconstruction method using a short hamstring graft. *Orthop Traumatol Surg Res* 2011;97:555-559.
  9. Colombet P, Graveleau N, Jambou S. Incorporation of hamstring grafts within the tibial tunnel after anterior cruciate ligament reconstruction: Magnetic resonance imaging of suspensory fixation versus interference screws. *Am J Sports Med* 2016;44:2838-2845.
  10. Lubowitz JH. All-inside anterior cruciate ligament graft link: Graft preparation technique. *Arthrosc Tech* 2012;1: e165-e168.