

## Technical Note

# Patellar Tendon Reconstruction Using Hamstring Tendon and Adjustable Suspensory Cortical Fixation

Jordan Ovigue, M.D., Nicolas Graveleau, M.D., and Nicolas Bouguennec, M.D.

**Abstract:** Chronic patellar tendon rupture is a rare injury; extensor mechanism impairment leads to great disability in daily life. The delayed diagnosis and reconstruction of chronic patellar tendon ruptures are technically challenging. Numerous surgical procedures have been described with bone-tendon-bone graft, hamstring graft, artificial ligament, and allograft. We describe safe, reproducible anatomic reconstruction of the patellar tendon using hamstring tendon and adjustable suspensory fixation. After harvesting of the hamstrings, the graft is prepared with 2 adjustable suspensory fixation devices. Then, a complete tibial tunnel and a patellar tunnel with a socket are drilled with the appropriate diameter, and the graft is pulled through the tunnels. Finally, the suspensory fixation devices on the tibial and patellar sides are tensioned. The aim of this procedure is to obtain complete mobility of the knee, using a procedure similar to anterior cruciate ligament reconstruction in graft preparation.

Chronic patellar tendon rupture is a rare disabling injury that is technically difficult to repair. Injuries to the patellar tendon occur most commonly in patients younger than 40 years. The impairment of the extensor mechanism results in great functional disability with deterioration in sports activity or daily life owing to loss of knee extension, making surgical treatment the gold-standard therapy. Techniques of reconstruction of the patellar tendon have changed over the past few decades. Restoration of the long-term extension and function of the knee joint remains the basic principle of any treatment strategy to avoid severe sequelae. Primary repair is indicated for acute patellar tendon rupture. Reconstructive surgery for chronic rupture is typically required because of quadriceps atrophy, proximal patellar migration, poor tissue quality, and

knee stiffness. Several methods for reconstruction of the patellar tendon have been described: bone-tendon-bone graft, ipsilateral gracilis and semitendinosus graft, artificial ligament, and allograft.<sup>1</sup> Because it is a rare condition with many described treatment techniques, no consensus on the optimal management has been reached. We describe our technique using adjustable suspensory fixation on the femoral and tibial sides with 6-strand hamstring tendon.

## Surgical Technique

### Patient Positioning

Patellar tendon reconstruction is performed with the patient under general anesthesia in the supine position; an air tourniquet is applied to the base of the limb at a pressure of 300 mm Hg. The lateral stress post is placed at the level of the tourniquet, whereas the footrest is positioned so that the knee is flexed to 90°. The patient is then prepared and draped in the usual sterile fashion.

### Surgical Approach

A midline longitudinal incision is used and extended to expose the patella, patellar tendon, and tibial tuberosity. All scars in the remnants of the patellar tendon are excised. Then, the patella and tibial tuberosity are prepared to receive the graft.

### Graft Preparation

The hamstrings (semitendinosus and gracilis) are harvested through the midline incision with a special

*From the Sports Clinic of Bordeaux-Mérignac (J.O., N.G., N.B.), Mérignac; and Laboratory of Anatomy, Hôpital Pellegrin, Bordeaux University Hospital (J.O.), Bordeaux, France.*

*The authors report the following potential conflicts of interest or sources of funding: N.G. receives grant support, personal fees, and nonfinancial support from SBM. N.B. receives personal fees and nonfinancial support from SBM. Full ICMJE author disclosure forms are available for this article online, as supplementary material.*

*Received December 7, 2018; accepted March 1, 2019.*

*Address correspondence to Jordan Ovigue, M.D., Centre of Orthopaedic Sports Surgery, Bordeaux-Mérignac 33700. E-mail: Jordan06021990@hotmail.fr*

*© 2019 by the Arthroscopy Association of North America. Published by Elsevier. This is an open access article under the CC BY-NC-ND license (<http://creativecommons.org/licenses/by-nc-nd/4.0/>).*

*2212-6287/181481*

*<https://doi.org/10.1016/j.eats.2019.03.001>*

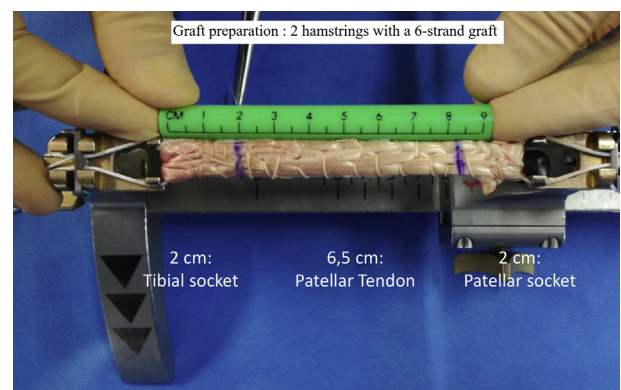
**Table 1.** Surgical Steps, Tips and Pearls, and Pitfalls of Technique

Surgical Step	Tips and Pearls	Pitfalls
Graft harvesting	<ul style="list-style-type: none"> <li>The hamstrings are harvested through the midline incision. A special stripper (ConMed Linvatec) is required to make sure the whole tendon is harvested.</li> </ul>	<ul style="list-style-type: none"> <li>Using an open stripper poses a major risk of cutting the proximal end of the tendon, thus reducing the tendon length and making the graft too short.</li> </ul>
Graft preparation	<ul style="list-style-type: none"> <li>The figure-of-8 stitch requires adequate preparation of the first loop of the graft. The suture continues on 1 edge of the graft and then returns to the other edge.</li> <li>The length of the graft in the patellar and tibial sockets should be at least 20 mm for good integration.</li> </ul>	<ul style="list-style-type: none"> <li>Extreme care must be taken with the first figure-of-8 stitch to avoid going through the Pullup XL loop's thread because this would make tightening the loop impossible.</li> <li>Preoperatively, assessment of the patellar height, with the Caton-Deschamps index on the contralateral knee radiograph, is essential for proper planning of the reconstruction because the patella is retracted proximally. The total length of the graft to be prepared may be calculated.</li> </ul>
Patellar tunnel drilling	<ul style="list-style-type: none"> <li>The patellar tunnel must be in the axis of the patella to avoid cartilage erosion.</li> </ul>	<ul style="list-style-type: none"> <li>All scars in the remnants of the patellar tendon are excised to achieve the best position.</li> <li>The diameter of the patellar socket must be &lt;11 mm.</li> </ul>
Tibial tunnel drilling	<ul style="list-style-type: none"> <li>The tibial tuberosity tunnel should be next to the tendon patellar insertion.</li> <li>For the second tunnel, an angle of 100° is necessary between the 2 tunnels; otherwise, the EndoButton is blocked during graft passage.</li> </ul>	<ul style="list-style-type: none"> <li>A staple can be placed to protect the bone bridge between the 2 tibial tunnels.</li> </ul>
Graft passage	<ul style="list-style-type: none"> <li>The standard Pullup device or the Pullup XL device is pulled with traction on the blue thread.</li> </ul>	<ul style="list-style-type: none"> <li>The surgeon should pull on the blue thread to tilt the Pullup device and after taking the set of threads, pull in the axis to pass the EndoButton through the bone tunnel.</li> </ul>

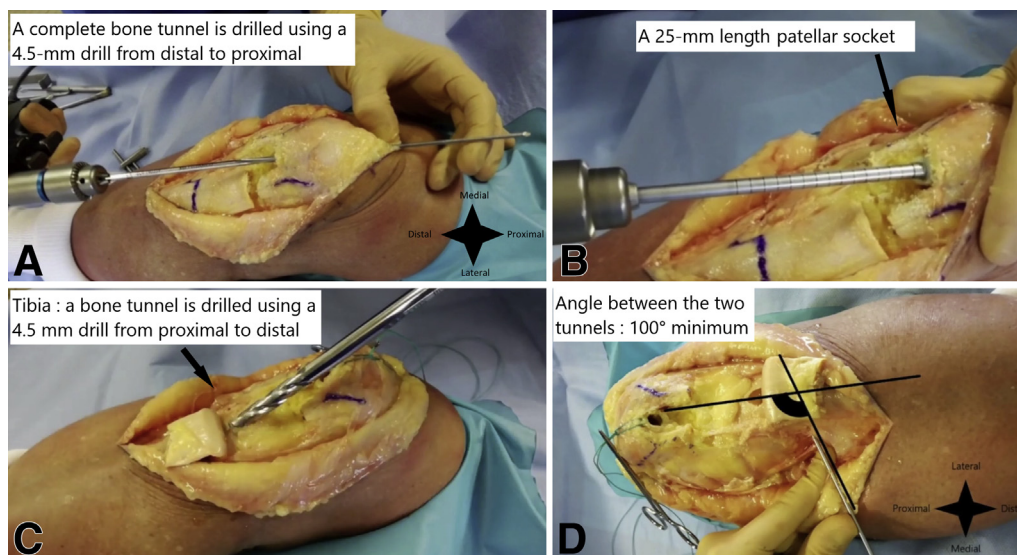
stripper (ConMed Linvatec, Largo, FL) (Table 1). Graft preparation is performed in the same manner as preparation for anterior cruciate ligament reconstruction with a short graft (4-strand semitendinosus) except that 2 hamstrings are used with a 6-strand graft.<sup>2</sup> The GraftTech table (SBM, Lourdes, France) is then equipped with 2 fixation devices: a standard Pullup device (SBM) on the patellar side and a Pullup XL device (SBM) on the tibial side. Graft preparation begins with a crucial step: The distal part of the graft is used to make a loop that is passed through the Pullup loops and secured with a temporary clamp. The graft goes through the Pullup XL loop and then returns to the Pullup device; this operation is repeated to obtain a 6-strand graft. Stitching begins with 2 figure-of-8 stitches to lock the first graft loop (Table 1). At this stage, the diameter and length of the graft are measured. We aim for a final length of 10 to 12 cm depending on the patient's height: 20 mm for the patellar socket, between 60 and 80 mm for the patellar tendon, and 20 mm for the tibial tunnel (Fig 1). The length of the patellar tendon is calculated based on the radiographic contralateral knee profile using the Caton-Deschamps index.<sup>3</sup> The surgeon marks the position 20 mm from the end of the patella and tibia where the tendon is planned to be transplanted. The graft is trialed through a graft-sizing block to measure the graft diameter and ensure proper fit. The autograft diameter is a minimum of 8.0 mm and maximum of 10.5 mm. Finally, the graft is placed under tension and covered in moist gauze.

### Tunnel Preparation

In the first step, for the patella, a complete bone tunnel is drilled using a 4.5-mm drill from distal to proximal (Fig 2A, Table 1). A 25-mm-long patellar socket is then drilled on the distal patellar side using a router and adjusted to the diameter of the graft (Fig 2B). In the second step, for the tibial tuberosity, a bone tunnel is drilled using a router and adjusted to the diameter of the graft from proximal to distal. A second



**Fig 1.** Graft preparation for patellar tendon reconstruction. Graft preparation is performed in the same manner as preparation for anterior cruciate ligament reconstruction with a short graft (4-strand semitendinosus) except that 2 hamstrings are used with a 6-strand graft. We aim for a final length of 10 to 12 cm depending on the patient's height: 20 mm for the patellar socket, between 60 and 80 mm for the patellar tendon, and 20 mm for the tibial tunnel.



**Fig 2.** A left knee is shown with the patient in the supine position and the knee flexed about 30° (superior view). (A) For the patella, a complete bone tunnel is drilled using a 4.5-mm drill from distal to proximal. (B) A 25-mm-long patellar socket, adjusted to the diameter of the graft, is drilled. (C) For the tibia, a bone tunnel is drilled using a 4.5-mm drill from proximal to distal. (D) A second complete tunnel is pierced from the medial side of the tibia to join the first tunnel. An angle of 100° is necessary between the 2 tunnels; otherwise, the EndoButton is blocked during graft passage.

complete tunnel is pierced from the medial side of the tibia to join the first tunnel (Fig 2C, Table 1). An angle of 100° is necessary between the 2 tunnels; otherwise, the Pullup XL device is blocked during graft passage and the bone bridge may collapse (Fig 2D).

### Patellar Tendon Reconstruction

In step 1, the Pullup XL device is pulled until the button is seated outside the tibial tunnel after traction is applied on the blue thread (Fig 3B). The blue thread is pulled to tilt the Pullup device and after the set of threads is taken, the axis is pulled in to pass the EndoButton (Smith & Nephew Endoscopy, Andover, MA) through the bone tunnel (Video 1).

In step 2, the patellar adjustable graft loop is pulled into the patellar tunnel until the mark on the graft loop reaches the tunnel entrance (Fig 3C). To achieve this, the surgeon has to pull on the blue thread of the Pullup device.

In step 3, the knee is flexed to 20°, and the suspensory fixation devices on the tibial and patellar sides are tensioned. The length of the Pullup loop is reduced by alternately pulling on the white thread (Fig 4, Video 1). In step 4, a staple can be placed to protect the bone bridge between the 2 tibial tunnels.

Postoperatively, radiographs are taken. The goal for the patellar height is a Caton-Deschamps index similar to that on the contralateral side.<sup>3</sup>

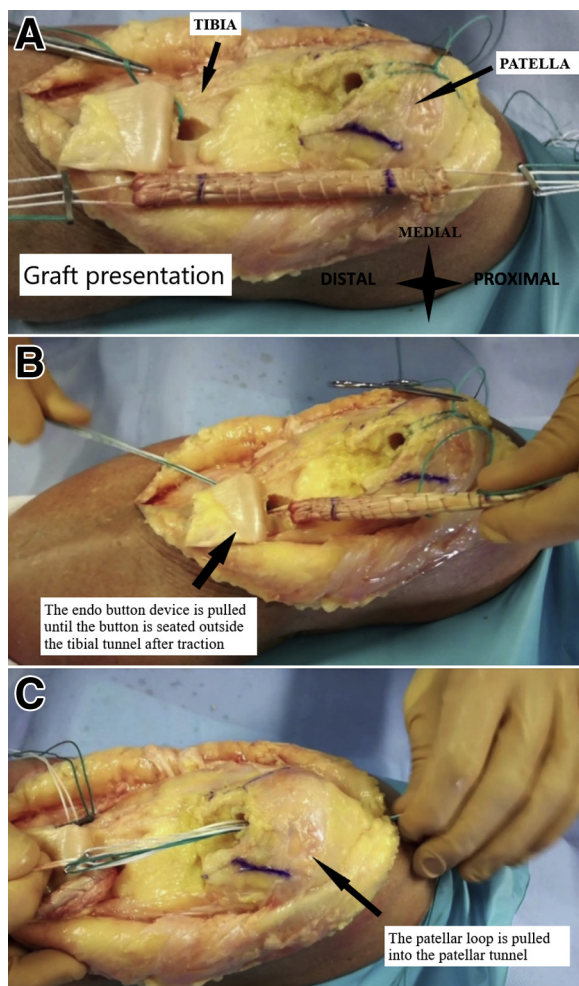
### Postoperative Rehabilitation

The patient is initially treated with a splint for 8 weeks. Immediately, complete weight bearing with crutches is allowed until sufficient motion and strength allow for unassisted ambulation, around the thirtieth day. Quadriceps contraction exercises are started just after surgery. Physiotherapy is initiated to move the knee between 0° and 45° at 3 weeks and 60° at 6 weeks.

### Discussion

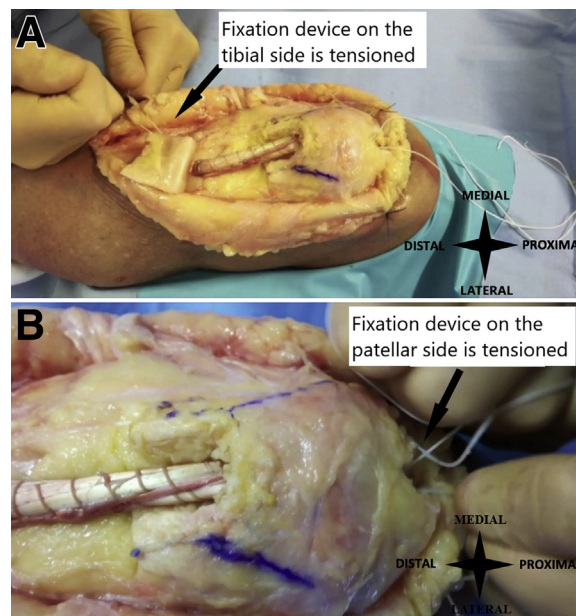
Chronic patellar tendon rupture is usually unilateral and is commonly reported as a result of athletic injury.<sup>4</sup> This disruption occurs after failure of primary repair or misdiagnosis at the time of the first visit without treatment.

Several alternative techniques have been reported, but no large series exist and late treatment of patellar tendon rupture is still controversial. Contralateral bone-tendon-bone graft,<sup>5</sup> ipsilateral gracilis and semitendinosus graft,<sup>1,6</sup> artificial ligament,<sup>7,8</sup> and allograft<sup>9,10</sup> have been described for this surgical procedure. The influence of graft choice on knee function has not been evaluated. Using cortical fixation on the femoral and tibial sides, the described technique allows strong fixation.<sup>11,12</sup> Because it is an



**Fig 3.** Left knee, superior view. (A, B) The EndoButton device is pulled until the button is seated outside the tibial tunnel after traction is applied on the blue thread. (C) The patellar adjustable graft loop is pulled into the patellar tunnel until the mark on the graft loop reaches the tunnel entrance.

adjustable fixation, it also allows the surgeon to adapt the length of the reconstruction to the radiologic operative control. Another advantage is the lack of donor-site morbidity regarding knee function when hamstring is used, similarly to anterior cruciate ligament reconstruction. In contrast, contralateral autograft composed of a block of tibial bone, the middle third of the patellar ligament, and a block of the patella is associated with a high iatrogenic risk to the contralateral extensor mechanism. Preoperatively, assessment of the patellar height, using the Caton-Deschamps index<sup>13</sup> on the contralateral knee radiograph, is essential for proper planning of the reconstruction because the patella is retracted proximally. Postoperatively, the secure and strong fixation allows complete weight bearing and physiotherapy with



**Fig 4.** Left knee, superior view. The knee is flexed to 20°, and the suspensory fixation devices on the tibial (A) and patellar (B) sides are tensioned. The length of the Pullup loop is reduced by alternately pulling on the white thread.

mobilization the day after surgery. Furthermore, removal of these materials is not necessary.

We have described our system for patellar tendon reconstruction with 2 adjustable cortical buttons. We think that the adjustable suspensory fixation helps spread out the tension and determine the patellar height necessary for function of the knee joint. Furthermore, the Pullup fixation is the same system used in reconstruction of the anterior cruciate ligament with a short graft, so it is easy to apprehend by the surgeon who already uses it (Table 2).

**Table 2.** Advantages, Risks, and Limitations of Patellar Tendon Reconstruction Using Hamstring Tendon and Adjustable Suspensory Fixation

Advantages	
Uses only 2 adjustable suspensory fixation devices	
Provides direct tension of reconstruction	
Uses similar procedure to anterior cruciate ligament reconstruction in graft preparation	
Performs reduction of patellar height with adjustable suspensory fixation	
Is reproducible and fast	
Risks	
Fractures of patella	
Collapse of tibial bone bridge	
Impossible reduction of patellar height	
Limitations	
If hamstrings have been harvested during previous operation	

## References

1. Gilmore JH, Clayton-Smith ZJ, Aguilar M, Pneumaticos SG, Giannoudis PV. Reconstruction techniques and clinical results of patellar tendon ruptures: Evidence today. *Knee* 2015;22:148-155.
2. Colombet P, Graveleau N. An anterior cruciate ligament reconstruction technique with 4-strand semitendinosus grafts, using outside-in tibial tunnel drilling and suspensory fixation devices. *Arthrosc Tech* 2015;4:e507-e511.
3. Thévenin-Lemoine C, Ferrand M, Courvoisier A, Damsin J-P, Ducou le Pointe H, Vialle R. Is the Caton-Deschamps index a valuable ratio to investigate patellar height in children? *J Bone Joint Surg Am* 2011;93:e35.
4. Siwek CW, Rao JP. Ruptures of the extensor mechanism of the knee joint. *J Bone Joint Surg Am* 1981;63:932-937.
5. Temponi EF, Camelo N, Tuteja S, et al. Reconstruction of chronic patellar tendon rupture with contralateral bone-tendon-bone autograft. *Knee Surg Sports Traumatol Arthrosc* 2017;25:2468-2473.
6. Pérez-García A, Esteban-Vico JR, García-Sánchez JM, et al. Autologous patellar tendon reconstruction after total knee arthroplasty infection with skin loss: Anatomical study and case report [published online January 29, 2019]. *J Knee Surg*, <https://doi.org/10.1055/s-0038-1677498>.
7. Talia AJ, Tran P. Bilateral patellar tendon reconstruction using LARS ligaments: Case report and review of the literature. *BMC Musculoskelet Disord* 2016;17:302.
8. Samagh SP, Huyke FA, Buchler L, Terry MA, Tjong VK. Treatment of a neglected patellar tendon rupture with a modified surgical technique: Ipsilateral semitendinosus autograft reconstruction with suture tape augmentation. *Case Rep Orthop* 2018;2018:2037638.
9. ElGuindy A, Lustig S, Servien E, et al. Treatment of chronic disruption of the patellar tendon in osteogenesis imperfecta with allograft reconstruction. *Knee* 2011;18:121-124.
10. Fiquet C, White N, Gaillard R, Servien E, Neyret P, Lustig S. Partial extensor mechanism allograft reconstruction for chronic patellar tendon disruption shows superior outcomes in native knees when compared to same technique following total arthroplasty. *Int Orthop* 2018;42:2591-2599.
11. Ferrari MB, Sanchez A, Moatshe G, Chahla J, DePhillipo N, Provencher MT. Proximal patellar tendon repair: Internal brace technique with unicortical buttons and suture tape. *Arthrosc Tech* 2017;6:e491-e497.
12. Ettinger M, Karkosch R, Horstmann H, et al. Biomechanical properties of adjustable extracortical graft fixations in ACL reconstruction. *J Exp Orthop* 2018;5:41.
13. Caton J, Deschamps G, Chambat P, Lerat JL, Dejour H. Patella infera. Apropos of 128 cases. *Rev Chir Orthop Reparatrice Appar Mot* 1982;68:317-325 [in French].